

Cheiloscopy: An Evolving Tool in Forensic Identification

Ganapathy Nalliapan, Maheshwari Ulaganathan, Yamunadevi Andamuthu, Maheswaran Thangadurai, Ilayaraja Vadivel, Tamil Thangam Periyasamy

Department of Oral and Maxillofacial Pathology, Vivekanandha Dental College for Women, Namakkal, Tamil Nadu, India

ABSTRACT

Cheiloscopy deals with the identification of humans based on lip traces. “Cheilos” is a Greek word meaning lip and “Scopy” means to examine. Human identification is one of the most challenging subjects. The lip print of every person is unique. The grooves present on the lips (sulci labiorum) are unique for every person and can be used in individual identification. In forensic identification, lip print pattern gives us important information and helps in individual identification. Lip prints are normal lines and fissures in the forms of wrinkles and grooves present in the zone of transition of human lip of inner oral labial mucosa and outer skin or vermilion border. The study of these grooves or furrows is known as cheiloscopy.

KEYWORDS: Cheiloscopy, forensic odontology, personal identification, sex determination

INTRODUCTION

Identification of humans is mandatory for personal social and legal reasons.^[1] Forensic odontology has been shown to play a major role in the identification of human leftovers. Since 49 AD, historical records also documented the use of forensic odontology.^[2]

In India, as well as all over the world today, crimes of varied nature are on the distension. Both educated elite of the society and criminals are using known techniques while committing their crimes, to put the forensic dentist, police, and the public off the scene. Hence, the role of crime detectives is not easy in this practical world.^[3]

The interesting aspect of cheiloscopy is that the wrinkles and grooves of the lips maintain the uniqueness and can be used as a record during the question of sex determination or in cases of personal identification. Although DNA profiling, fingerprint anthropometric data, and dental records can be used as standard methods, cheiloscopy plays a significant role.^[4] It is possible to identify lip patterns as early as the 6th week of the intrauterine life.^[5] They are unique, permanent, and unchangeable even after death and unique to each person except for monozygotic twins. The study shows that, even as age advances, the lip print pattern does not change.

Theory of uniqueness is a strong point used in the fingerprint analysis to assure the court of law. A likewise even lip print is unique for an individual and hence considers the potential for identification purpose. Thus, lip prints play a major role to verify the presence or absence of a person at the scene of crime. The professional conscience of dental surgeon to humankind is not only to provide an examination, investigation, diagnosis, and treatment of oral and orofacial lesions of local origins and oral manifestations of systemic diseases but also to attend to other community services and legal matters as well.^[3]

HISTORICAL PERSPECTIVE

The biological phenomenon of systems of furrows on the red part of human lips was first noted by anthropologist R. Fischer in 1902.^[6,7]

In 1961, the first research in Europe was carried out on the subjects of lip prints in Hungary. The examination started at the scene of crime, when lip traces were found on a glass door.^[1]

Address for correspondence: Dr. Ganapathy Nalliapan
Department of Oral and Maxillofacial Pathology, Vivekanandha
Dental College for Women, Elaiyampalayam, Namakkal,
Tamil Nadu, India.
E-mail: drganapathy.smilecare@yahoo.com

This is an open access journal, and articles are distributed under the terms of the Creative Commons Attribution-NonCommercial-ShareAlike 4.0 License, which allows others to remix, tweak, and build upon the work non-commercially, as long as appropriate credit is given and the new creations are licensed under the identical terms.

For reprints contact: reprints@medknow.com

How to cite this article: Nalliapan G, Ulaganathan M, Andamuthu Y, Thangadurai M, Vadivel I, Periyasamy TT. Cheiloscopy: An evolving tool in forensic identification. J Indian Acad Dent Spec Res 2018;5:37-41.

Access this article online	
Quick Response Code: 	Website: www.jiadsr.org
	DOI: 10.4103/jiadsr.jiadsr_32_17

In Poland, 1966, the interest in lip prints started, when accidentally a lip print was revealed on the window glass at the scene of burglary. Research was carried out later and its results were comparable to those achieved in Japan and Hungary.^[2]

In August 1966, during the fourth International Symposium of Forensic Medicine in Copenhagen, Dr. Martin Santos from Brazil presented his own classification of lip furrows and lines and described how these characteristic features can be used for identification.^[1]

In the period 1968–1971, two Japanese scientists, Y. Tsuchihashi and T. Suzuki, examined 1364 persons at the Department of Forensic Odontology at Tokyo University. With that research, it was established that the arrangement of lines on the red part of human lips is individual and unique to each human being. Then, in further research, the Japanese scientists examined the principles of the heredity of furrows on the red part of lips.^[4,5,8]

In 1974, Tsuchihashi carried out another study with greater number of participants as well as family groups. By comparing the lip prints of the twins with their parents, he found that they closely resembled one parent which adds strength to the theory of heredity of lip prints. He also found that following trauma to a lip, it resumed the groove pattern after healing.^[1]

In 1981, Cottone reported in his book outline Forensic Dentistry that cheiloscopy is one of the unique techniques used for person identification.^[5]

In 1982, a project was launched in the Forensic Institute of Warsaw University Criminal Law Department in cooperation with the former Forensic Institute of Milita in Warsaw with the aim of developing one cohesive cheiloscopy system practicable in forensic cheiloscopy. Lip prints were collected from 1500 persons (including 107 women) coming from various locations around the country. The age of volunteers varied from 5 to 60 years, and altogether >7000 traces of red part lips were examined. The examination determined the methods for revealing and securing the traces of the lips, the methods of acquiring the comparative material, and, more importantly, the detailed methods of cheiloscopic expertise.^[1]

In 1985, the methods of finding and recovery of lip traces, recovering comparative material, and the techniques employed to carry out expertise have been introduced into the casework of fingerprint department of the Central Forensic Laboratory of Police in Warsaw, Poland.^[1]

In 1990, Kasprzak conducted research for 5 years in 1500 persons to indicate the practical use of lip prints.^[9,10]

In 1999, the Federal Bureau of Investigation (FBI) and the Illinois state police conspired that lip prints are unique like fingerprints and are useful for identification.^[10]

Alvarez *et al.* (2000–2002) and Vahanwahal *et al.* (2000) gave the explanation that vermilion borders of the lips have minor salivary glands and sebaceous gland secretions and moisturizing property, which makes the latent lip prints available at most of the crime scenes.^[11]

Kundu S *et al.*, mentioned that, in a study by Castello *et al.* (2005) on luminous lip prints, he used luminescence as a special property for the search of invisible evidence in the scene of crime.^[11]

It was during the period 2000–2010 that studies were carried out by several researchers in India and other countries. Different aspects of lip prints among different groups of population were studied. Study on postmortem changes of lip prints was also carried out to find out the changes in anthropometric measurements of the lip region before and after fixation.^[12,13]

All these studies were in agreement with the Japanese research and thus helped in concluding that the cheiloscopic studies can be implemented as an auxiliary method of identification.^[12]

Prabhu *et al.* (2012) stated that lip prints can be properly recorded without the use of any recording medium with the help of suitable nonporous surface.^[12]

Kundu S *et al.*, mentioned that, lip print patterns are distinct for an individual. A statistically significant prevalence of curve and wavy form was seen in males and straight pattern in females.^[11]

Khanapure *et al.* (2014) summarized the view that statistically significant association existed between gender and lip print patterns, whereas the association between geographic location and lip print was not statistically significant. They also reached a conclusion that the distribution of lip prints is unique for males and females and the association between geographic location and lip print was not statistically significant.^[11]

Almuhaizia *et al.* (2014) presented a published manuscript on gender determination using cheiloscopy in the pediatric population, in which they commented critically that no two lip print patterns matched each other, thus establishing the uniqueness of lip prints.^[11]

LIP PRINTS AS AN AID

For sex determination

In a study conducted by Vahanwala-Parekh, the sex of the individual was determined as:

- Type I and I a patterns are dominant in females in the third and fourth quadrants, i.e., lower lip
- Type II pattern is common in males in the second quadrant, i.e., upper lip, left side.

Individuals with different patterns in all quadrants were common in males, whereas having the same pattern in all quadrants were seen in females.^[1,12]

For personal identification

The specific grooves present on the human lips play a major role in identification. Each lip print was measured for its length and then divided into six equal parts as upper right, upper middle, upper left, lower left, lower middle, and lower right.^[12]

CLASSIFICATION

- (1) Martin Santos Classification (1966)^[1]
 - I. Simple wrinkles
 - a. Straight lines
 - b. Angled lines
 - c. Sine-shaped curve.
 - II. Compound wrinkles
 - a. Bifurcated
 - b. Trifurcated
 - c. Anomalous.
- (2) Suzuki and Tsuchihashi Classification (1970)^[12,14,15] [Figure 1]:
 - Type I: Clear-cut grooves running vertically across the lip
 - Type I': Straight grooves which disappear half way instead of covering the entire breadth of the lip
 - Type II: Fork grooves in their course
 - Type III: Intersecting grooves
 - Type IV: Reticulate grooves
 - Type V: Undermined
- (3) Raynaud's Classification:^[12]
 - a. Complete vertical
 - b. Incomplete vertical
 - c. Complete bifurcated
 - d. Incomplete bifurcated

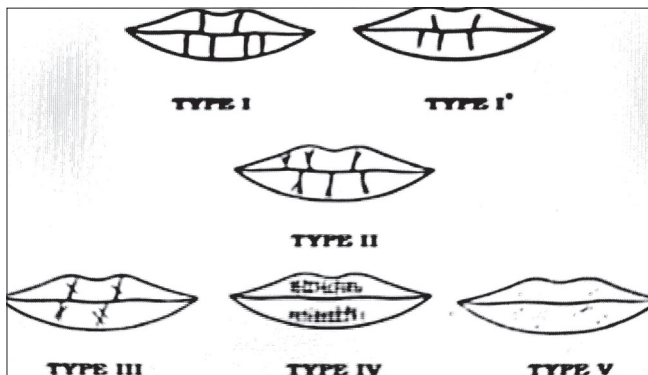


Figure 1: Suzuki and Tsuchihashi classification (1970)

- e. Complete branched
- f. Incomplete branched
- g. Reticular pattern
- h. X or coma form
- i. Horizontal
- j. Other forms (ellipse, triangle).

- (4) Afchar–Bayat Classification (1979):^[1]
 - A1: Vertical and straight grooves, covering the whole lip
 - A2: Vertical and straight grooves, but not covering the whole lip
 - B1: Straight-branched grooves
 - B2: Angulated-branched grooves
 - C: Converging grooves
 - D: Reticular pattern grooves
 - E: Other grooves.
- (5) The sex of the individual was determined as given by Vahanwala *et al.*^[3]
 1. Type I and I' pattern dominant: Female
 2. Type I and II pattern dominant: Female
 3. Type III pattern dominant: Male
 4. Type IV pattern: Male
 5. Type V varied patterns: Male.
- (6) Recently for the basis of the classification, only 10 mm portion of the middle part of the lower lip is used.^[1,3]
 - Linear “L” – if the lines prevail
 - Bifurcation “R” – if the bifurcation is dominant
 - Reticular “S” – if the lines cross
 - Undermined “N” – when no superiority can be established.
- (7) The next step is, 23 types of individual features are described to establish individual features of patterns of the lines [Figure 2].^[3,4]

MERIT OF LIP PRINT

When the prints are not clear, i.e., only the shape of the lip is printed, individual identification of a human being is very difficult, based on this trace.^[1] In these cases, it is allowed to examine the substance which constituted the trace, e.g., saliva as a biological tracing.^[1] The huge potential for DNA typing from the lip print is evident.^[3] The lines are printed unclearly in the case where the lips are covered with food or cosmetics and the trace will have the shape of the stain and can be subjected to chemical examination, to determine the substance covering the lips.^[4] When a lip print is seen at the crime scene, the character of the event, the number of person involved, sexes, cosmetics used, habits, occupational traits, and the pathological changes of lips can be concluded.^[4] Trace with clear visible lines and individual elements gives individual identification of human being. As

S.No	Pattern of Lip line	Individual features	S.No	Pattern of Lip line	Individual features
01	An eye	⊙	15	Simple opening	┌
02	Hook	┌	16	Closing top bifurcation	┐
03	Bridge	—	17	Pentagonal arrangement	⬠
04	Line	—	18	Branch like top bifurcation	┐
05	Dot	•	19	Star like bifurcation	✱
06	Rectangle	▭	20	Fence	###
07	Triangle	▴	21	Branch like bottom bifurcation	└
08	Group of dots	•••	22	Double fence	### ##
09	Simple top bifurcation	┌	23	Hexagonal arrangement	⬡
10	Simple bottom bifurcation	└			
11	Double eye	⊙⊙			
12	Crossing lines	×			
13	Crossing bottom bifurcation	└			
14	Delta like opening	∇			

Figure 2: Individual features of patterns of the lines

they are unique, lip prints have the same value as dactyloscopic (fingerprint) traces.^[1]

DEMERITS OF LIP PRINTS

The lip crease pattern is on the vermilion border of the lip, which is the mobile portion of the lip. According to the pressure, direction, and method used in taking the print, lip prints may vary in appearance. This is the fact why the same person can produce different lip prints. If lipstick is used as a recording medium, the amount applied may also affect the print. Smudging of the lip prints may occur. Manual register presents with problems due to the possibility of some subjectivity. Existence of some pathological conditions such as lymphangiomas, congenital lip, fistula, lip scleroderma, Melkersson–Rosenthal syndrome, syphilis, and lip cheilitis are the other factors which can invalidate the cheiloscopic study.^[9]

APPLICATION OF CHEILOSCOPY IN MODERN SCIENCES

Cheiloscropy is analogous to fingerprint analysis. Lip prints added evidence to a crime scene, and this is valuable, especially in cases of lacking other evidence, like fingerprints.^[3]

Cheiloscropy:

- A deterministic aid in forensic sex determination
- A tool in crime investigation
- An aid for personal identification.

LIP PRINT AS A VICTIM IN COURT

The use of lip print in court is rare and its acceptance is questionable. Professor Jay Siegel (Professor of Forensic Science and Associate Director of the School of Criminal Justice, Michigan State University) considers lip print evidence to be admissible in court. FBI has used lip prints as a means of positive identification only once.^[2]

CONCLUSION

Since lip prints remain stable as age advances for person's life and are unique to individual, even in twins and family members, it may be used as a record for the individual along with the fingerprints. Cheiloscropy holds the potential to identify the sex and in personal identification. Collection of the visible and latent lip prints with a suitable transferring and recording media is important.^[2] The tremendous research done in the field of cheiloscropy and further studies concerning standardization of methods to analyze the lip prints by the use of biometric system is in process.^[3] Thus, lip print has the potential as supplementary tools for identification purpose.

Financial support and sponsorship

Nil.

Conflicts of interest

There are no conflicts of interest.

REFERENCES

1. Sivapathasundharam B, Prakash PA, Sivakumar G. Lip prints (cheiloscropy). *Indian J Dent Res* 2001;12:234-7.
2. Augustine J, Barpande SR, Tupkari JV. Cheiloscropy as an adjunct to forensic identification: A study of 600 individuals. *J Forensic Odontostomatol* 2008;26:44-52.
3. More C, Patil R, Asrani M, Gondivkar S, Patel H. Cheiloscropy – A review. *Indian J Forensic Med Toxicol* 2009;3:17-20.
4. Sharma P, Saxena S, Rathod V. Cheiloscropy: The study of lip prints in sex identification. *J Forensic Dent Sci* 2009;1:24-7.
5. Joseph A, Kuriakose SL, Ismail M, Jiju V, Mathews S. An updated review on cheiloscropy. *Eur J Pharm Med Res* 2015;2:286-9.
6. Saraswathi TR, Mishra G, Ranganathan K. Study of lip prints. *J Forensic Dent Sci* 2009;1:28-31.
7. Gupta N, Gupta R, Ingale DI, Bhuyar C, Nucchi UC, Hibare SR. Role of lip prints in personal identification. *Int J Curr Res Rev* 2013;5:25-8.
8. Kundu S, Gangrade P, Jatwar R, Rathina D, Rathia D. Cheiloscropy – A diagnostic and deterministic mirror for establishment of person identification and gender discrimination: A study participated by Indian medical students to aid legal proceedings and criminal investigations. *J Exp Clin Anat* 2016;15:31-42.
9. Prabhu VR, Dinkar DA, Prabhu DV. Collection of lip prints as a forensic evidence at the crime scene – An insight. *J Oral Health Res* 2010;1:129-35.
10. Amith HV, Ankola VA, Nagesh L. Lip prints-can it aid in individual identification. *J Oral Health Community Dent*

- 2011;5:113-8.
11. Prabhu RV, Dinkar AD, Prabhu VD, Rao PK. Cheiloscopy: Revisited. *J Forensic Dent Sci* 2012;4:47-52.
 12. Dineshshankar J, Ganapathi N, Yoithapprabhunath TR, Maheswaran T, Kumar MS, Aravindhan R, *et al.* Lip prints: Role in forensic odontology. *J Pharm Bioallied Sci* 2013;5:S95-7.
 14. Dongarwar GR, Bhowate RR, Degwekar SS. Cheiloscopy-method of person identification and sex determination. *JCDR* 2013;2:2-4.
 13. Neelkamal, Jyoti, Divya. Cheiloscopy: A tool for sex identification. *Int J Forensic Sci Pathol* 2016;4:221-6.
 15. Rajendran R, Sivapathasundharam B. *Shafer's Textbook of Oral Pathology*. 7th ed. India: Elsevier Health Sciences; 2016.